

Johannes W. Rohen
Chihiro Yokochi
Elke Lütjen-Drecoll

Color Atlas of Anatomy



A Photographic Study
of the Human Body

Seventh Edition



Coeditons in 20 Languages

Johannes W. Rohen
Chihiro Yokochi
Elke Lütjen-Drecoll

Color Atlas of Anatomy

A Photographic Study
of the Human Body

Seventh Edition

With 1211 Figures,
1117 in Color,
and 94 Radiographs, CT and MRI Scans

 Wolters Kluwer | Lippincott Williams & Wilkins
Health
Philadelphia • Baltimore • New York • London
Buenos Aires • Hong Kong • Sydney • Tokyo

 **Schattauer**

Prof. Dr. med. Dr. med. h.c. Johannes W. Rohen
Anatomisches Institut II der Universität Erlangen-Nürnberg
Universitätsstraße 19, 91054 Erlangen, Germany

Chihiro Yokochi, M.D.
Professor emeritus, Department of Anatomy
Kanagawa Dental College, Yokosuka, Kanagawa, Japan
Correspondence to:
Prof. Chihiro Yokochi, c/o Igaku-Shoin Ltd., 1-28-23 Hongo,
Bunkyo-ku Tokyo 113-8719, Japan

Prof. Dr. med. Elke Lütjen-Drecoll
Anatomisches Institut II der Universität Erlangen-Nürnberg
Universitätsstraße 19, 91054 Erlangen, Germany

With Collaboration of
Kyung W. Chung, Ph.D.
David Ross Boyd Professor & Vice Chairman
Samuel Roberts Noble Foundation Presidential Professor
Director, Advanced Human Anatomy
University of Oklahoma, College of Medicine
Department of Cell Biology

Copyright ©
Fourth Edition, 1998
Fifth Edition, 2002
Sixth Edition, 2006
Seventh Edition, 2011 by
Schattauer GmbH,
Hölderlinstraße 3, 70174 Stuttgart, Germany; <http://www.schattauer.de>, and
Lippincott Williams & Wilkins, a Wolters Kluwer business

351 West Camden Street 530 Walnut Street
Baltimore, MD 21201 Philadelphia, PA 19106

All rights reserved. This book is protected by copyright. No part of this book may be reproduced or transmitted in any form or by any means, including as photocopies or scanned-in or other electronic copies, or utilized by any information storage and retrieval system without written permission from the copyright owner, except for brief quotations embodied in critical articles and reviews. Materials appearing in this book prepared by individuals as part of their official duties as U.S. government employees are not covered by the above-mentioned copyright. To request permission, please contact Lippincott Williams & Wilkins at 530 Walnut Street, Philadelphia, PA 19106, via email at permissions@lww.com, or via website at lww.com (products and services).

9 8 7 6 5 4 3 2 1

Library of Congress Cataloging-in-Publication data has been applied for and is available upon request.

DISCLAIMER

Care has been taken to confirm the accuracy of the information present and to describe generally accepted practices. However, the authors, editors, and publisher are not responsible for errors or omissions or for any consequences from application of the information in this book and make no warranty, expressed or implied, with respect to the currency, completeness, or accuracy of the contents of the publication. Application of this information in a particular situation remains the professional responsibility of the practitioner; the clinical treatments described and recommended may not be considered absolute and universal recommendations.

The authors, editors, and publisher have exerted every effort to ensure that drug selection and dosage set forth in this text are in accordance with the current recommendations and practice at the time of publication. However, in view of ongoing research, changes in government regulations, and the constant flow of information relating to drug therapy and drug reactions, the reader is urged to check the package insert for each drug for any change in indications and dosage and for added warnings and precautions. This is particularly important when the recommended agent is a new or infrequently employed drug.

Some drugs and medical devices presented in this publication have Food and Drug Administration (FDA) clearance for limited use in restricted research settings. It is the responsibility of the health care provider to ascertain the FDA status of each drug or device planned for use in their clinical practice.

To purchase additional copies of this book, call our customer service department at (800) 638-3030 or fax orders to (301) 223-2320. International customers should call (301) 223-2300.

Visit Lippincott Williams & Wilkins on the Internet: <http://www.lww.com>. Lippincott Williams & Wilkins customer service representatives are available from 8:30 am to 6:00 pm, EST.

ISBN: 9781582558561

Preface to the Seventh Edition

This new edition was revised and structured anew in different ways. Each chapter is provided with an introductory front page to give an overview of the topics of the chapter and short descriptions. The whole introductory chapter "General Anatomy" was newly arranged and supported with introductory texts, thus facilitating students to better understand the complicated "world" of gross anatomy. The large chapter 2 "Head and Neck" was split into 5 sub-chapters with an introductory page each. Furthermore, the drawings were revised and improved in many chapters and depicted more consistently. In most of the chapters new photographs taken from newly dissected specimens were incorporated.

The general structure and arrangement of the Atlas were maintained. The chapters of regional anatomy are consequently placed behind the systematic descriptions of the anatomical structures so that students can study – e.g. before dissecting an extremity – the systematic anatomy of bones, joints, muscles, nerves and vessels. For studying the photographs of the specimens the use of a magnifier might be helpful. The enormous plasticity of the photos is surprising, especially at higher magnifications.

In many places new MRI and CT scans were added to give consideration to the new imaging techniques which become more and more important for the student in preclinics. We would like to express our sincere thanks to Prof. Heuck, Munich, who provided us with the MRI scans.

We would like to express our great gratitude to all coworkers who helped to make the *Color Atlas of Anatomy* a success. We are particularly indebted to those who dissected new specimens with great skill and knowledge, particularly to Jeff Bryant (member of our staff) and Dr. Martin Rexer (now Klinikum Fürth, Germany), who prepared most of the new specimens of the fifth, sixth and seventh edition. We would also like to thank Dr. K. Okamoto (now Nagasaki, Japan), who dissected many excellent specimens of the fourth edition, also included in the fifth edition. Furthermore, we are greatly indebted to Prof. W. Neuhuber and his coworkers for their great efforts in supporting our work.

The specimens of the previous editions also depicted in this volume were dissected with great skill and enthusiasm by Prof. Dr. S. Nagashima (now Nagasaki, Japan), Dr. Mutsuko Takahashi (now Tokyo, Japan), Dr. Gabriele Lindner-Funk (Erlangen, Germany), Dr. P. Landgraf (Erlangen, Germany), and Miss Rachel M. McDonnell (now Dallas, Texas, USA).

We are greatly indebted to Prof. Kyung Won Chung, Ph.D., Director of Medical Gross Anatomy, University of Oklahoma, USA, Dept. of Cell Biology, for his careful corrections of the proofs of the new edition.

In the underlying seventh edition photographs of the surface anatomy of the human body were included again. We omitted marks and indications in order not to affect the quality of the pictures.

Despite numerous additions and amendments the size of the volume did not increase so that students both in preclinics and in clinics are offered an atlas easy to handle and cope with.

While preparing this new edition, the authors were reminded of how precisely, beautifully, and admirably the human body is constructed. If this book helps the student or medial doctor to appreciate the overwhelming beauty of the anatomical architecture of tissues and organs in the human, then it greatly fulfils its task. Deep interest and admiration of the anatomical structures may create the "love for man", which alone can be considered of primary importance for daily medical work.

We would like to express our great gratitude to all coworkers for their skilled work. Without their help the improvements of the *Color Atlas of Anatomy* would not have been possible. We would also like to express our sincere thanks to those at Schattauer GmbH, Stuttgart, Germany, Lippincott, Williams & Wilkins, Baltimore, Maryland, USA, and Igaku-Shoin, Tokyo, Japan, who always listened to our suggestions and invested again a great deal of their effort into improving this book.

Acknowledgements

We would also like to express our many thanks to Prof. W. Bautz (Radiologisches Institut, University Erlangen-Nürnberg, Germany) and Prof. A. Heuck (Radiologisches Zentrum, München-Pasing, Germany), who provided the newly included excellent CT and MRI scans.

We are also greatly indebted to Mr. Hans Sommer (SOMSO Co., Coburg, Germany), who kindly provided a number of excellent bone specimens.

Finally, we would like to express our great gratitude to our photographer, Mr. Marco Gößwein, who contributed the very excellent macrophotos. Excellent and untiring work was done by our secretaries, Mrs. Lisa Köhler and Elisabeth Wascher, and as well by our artists, Mr. Jörg Pekarsky and Mrs. Annette Gack, who not only performed excellent new drawings but revised effectively the layout of the new edition.

Last but not least, we would like to express our sincere thanks to all scientists, students, and other coworkers, particularly to the ones at the publishing companies themselves.

Erlangen, Germany; Spring 2010

J. W. Rohen
C. Yokochi
E. Lütjen-Drecoll

Preface to the First Edition

Today there exist any number of good anatomic atlases. Consequently, the advent of a new work requires justification. We found three main reasons to undertake the publication of such a book.

First of all, most of the previous atlases contain mainly schematic or semischematic drawings which often reflect reality only in a limited way; the third dimension, i.e., the spatial effect, is lacking. In contrast, the photo of the actual anatomic specimen has the advantage of conveying the reality of the object with its proportions and spatial dimensions in a more exact and realistic manner than the "idealized", colored "nice" drawings of most previous atlases. Furthermore, the photo of the human specimen corresponds to the student's observations and needs in the dissection courses. Thus he has the advantage of immediate orientation by photographic specimens while working with the cadaver.

Secondly, some of the existing atlases are classified by systemic rather than regional aspects. As a result, the student needs several books each supplying the necessary facts for a certain region of the body. The present atlas, however, tries to portray macroscopic anatomy with regard to the regional and stratigraphic aspects of the object itself as realistically as possible. Hence it is an immediate help during the dissection courses in the study of medical and dental anatomy.

Another intention of the authors was to limit the subject to the essential and to offer it didactically in a way that is self-explanatory. To all regions of the body we added schematic drawings of the main tributaries of nerves and vessels, of the course and mechanism of the muscles, of the nomenclature of the various regions, etc. This will enhance the understanding of the details seen in the photographs. The complicated architecture of the

skull bones, for example, was not presented in a descriptive way, but rather through a series of figures revealing the mosaic of bones by adding one bone to another, so that ultimately the composition of skull bones can be more easily understood.

Finally, the authors also considered the present situation in medical education. On one hand there is a universal lack of cadavers in many departments of anatomy, while on the other hand there has been a considerable increase in the number of students almost everywhere. As a consequence, students do not have access to sufficient illustrative material for their anatomic studies. Of course, photos can never replace the immediate observation, but we think the use of a macroscopic photo instead of a painted, mostly idealized picture is more appropriate and is an improvement in anatomic study over drawings alone.

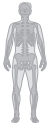The majority of the specimens depicted in the atlas were prepared by the authors either in the Dept. of Anatomy in Erlangen, Germany, or in the Dept. of Anatomy, Kanagawa Dental College, Yokosuka, Japan. The specimens of the chapter on the neck and those of the spinal cord demonstrating the dorsal branches of the spinal nerves were prepared by Dr. K. Schmidt with great skill and enthusiasm. The specimens of the ligaments of the vertebral column were prepared by Dr. Th. Mokuschi, and a great number of specimens in the chapter of the upper and lower limb was very carefully prepared by Dr. S. Nagashima, Kurume, Japan.

Once again, our warmest thanks go out to all of our coworkers for their unselfish, devoted and highly qualified work.

Erlangen, Germany; Spring 1983

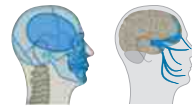J.W. Rohen
C. Yokochi

Contents



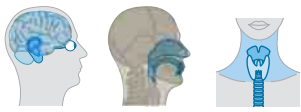1 General Anatomy 1

Architectural Principles of the Human Body _____	1
Position of the Inner Organs, Palpable Points, and Regional Lines _____	2
Planes and Directions of the Body _____	4
Osteology _____	6
Skeleton of the Human Body _____	6
Bone Structure _____	8
Ossification of the Bones _____	9
Arthrology _____	10
Types of Joints _____	10
Architecture of the Joint _____	12
Myology _____	13
Shapes of Muscles _____	13
Structure of the Muscular System _____	14
Comparative Imaging of Skeletal and Muscular Structures in MRI and X-Ray _____	15
Organization of the Circulatory System _____	16
Organization of the Lymphatic System _____	17
Organization of the Nervous System _____	18



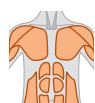
2 Head and Neck 19

2.1 Skull and Muscles of the Head _____	19
Bones of the Skull _____	20
Disarticulated Skull I _____	24
Sphenoidal and Occipital Bones _____	24
Temporal Bone _____	26
Frontal Bone _____	28
Calvaria _____	29
Base of the Skull _____	30
Skull of the Newborn _____	35
Median Sections through the Skull _____	36
Disarticulated Skull II _____	38
Ethmoidal Bone _____	38
Ethmoidal and Palatine Bones _____	39
Palatine Bone and Maxilla _____	40
Sphenoidal, Ethmoidal, and Palatine Bones _____	43
Maxilla, Zygomatic Bone, and Bony Palate _____	45
Pterygopalatine Fossa and Orbit _____	46
Orbit, and Nasal and Lacrimal Bones _____	47
Bones of the Nasal Cavity _____	48
Septum and Cartilages of the Nose _____	49
Maxilla and Mandible with Teeth _____	50
Deciduous and Permanent Teeth _____	51
Mandible and Dental Arch _____	52
Ligaments of the Temporomandibular Joint _____	53
Temporomandibular Joint _____	54
Temporomandibular Joint and Masticatory Muscles _____	55
Masticatory Muscles _____	56
Temporalis and Masseter Muscles _____	56
Pterygoid Muscles _____	57
Facial Muscles _____	58
Supra- and Infrahyoid Muscles _____	60
Section through the Cavities of the Head _____	62
Maxillary Artery _____	63
2.2 Cranial Nerves _____	64
Brain and Cranial Nerves _____	64
Trigeminal Nerve _____	68
Facial Nerve _____	70
Connection with the Brain Stem _____	71
Nerves of the Orbit _____	72
Base of the Skull with Cranial Nerves _____	74
Regions of the Head _____	76
Lateral Region _____	76
Retromandibular Region _____	80
Para- and Retropharyngeal Regions _____	83



2 Head and Neck

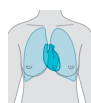2.3 Brain and Sensory Organs _____	84	2.4 Oral and Nasal Cavities _____	143
Position of Brain and Great Sensory Organs _____	84	Position of Oral and Nasal Cavities _____	143
Scalp and Meninges _____	85	Nasal Cavity _____	144
Meninges _____	86	Paranasal Sinuses _____	144
Dura Mater and Dural Venous Sinuses _____	86	Nerves and Arteries _____	146
Dura Mater _____	88	Sections through the Nasal and Oral Cavities _____	148
Pia Mater and Arachnoid _____	89	Oral Cavity _____	150
Brain _____	90	Muscles _____	150
Median Sections _____	90	Submandibular Triangle _____	152
Arteries and Veins _____	92	Salivary Glands _____	153
Arteries _____	93		
Arteries and the Arterial Circle of Willis _____	98	2.5 Neck and Organs of the Neck _____	154
Cerebrum _____	99	Organization and Regions of the Neck _____	154
Cerebellum _____	102	Muscles of the Neck _____	156
Dissections _____	104	Larynx _____	158
Limbic System _____	107	Cartilages and Hyoid Bone _____	158
Hypothalamus _____	108	Muscles _____	160
Subcortical Nuclei _____	109	Vocal Ligament _____	161
Ventricular System _____	112	Nerves _____	162
Brain Stem _____	114	Larynx and Oral Cavity _____	163
Coronal and Cross Sections _____	116	Pharynx _____	164
Horizontal Sections _____	118	Muscles _____	166
Auditory and Vestibular Apparatus _____	122	Vessels of the Head and Neck _____	168
Temporal Bone _____	125	Arteries _____	168
Middle Ear _____	126	Arteries and Veins _____	170
Auditory Ossicles _____	128	Veins _____	171
Internal Ear _____	129	Lymph Vessels and Nodes _____	172
Auditory Pathway and Areas _____	131	Regions of the Neck _____	174
Visual Apparatus and Orbit _____	132	Anterior Region _____	174
Eyeball _____	133	Lateral Region _____	178
Vessels of the Eye _____	134	Cervical and Brachial Plexuses _____	186
Extra-ocular Muscles _____	135		
Visual Pathway and Areas _____	137		
Layers of the Orbit _____	140		
Lacrimal Apparatus and Lids _____	142		



3 Trunk

187

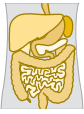Segmental Structure of the Trunk _____	187
Skeleton _____	188
Vertebrae _____	190
Vertebral Column and Thorax _____	192
Vertebral Joints _____	195
Costovertebral Joints and Intercostal Muscles _____	196
Costovertebral Joints _____	197
Ligaments _____	198
Joints Connecting to the Head _____	200
Vertebral Column of the Neck _____	203
Surface Anatomy of the Anterior Body _____	204
Female _____	204
Male _____	205
Thoracic Wall _____	206
Thoracic and Abdominal Walls _____	209
Vessels and Nerves _____	214
Inguinal Region _____	217
Male _____	217
Female _____	220
Back _____	221
Muscles _____	221
Nerves _____	226
Vertebral Canal and Spinal Cord _____	230
Nuchal Region _____	234



4 Thoracic Organs

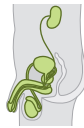243

Position of the Thoracic Organs _____	243
Respiratory System _____	246
Bronchial Tree _____	246
Projections of Lungs and Pleura _____	248
Lungs _____	249
Bronchopulmonary Segments _____	250
Heart _____	252
Myocardium _____	257
Valves _____	258
Function _____	260
Conducting System _____	261
Arteries and Veins _____	262
Regional Anatomy of the Thoracic Organs _____	264
Thymus _____	266
Heart _____	268
Pericardium _____	272
Epicardium _____	273
Posterior Mediastinum _____	274
Mediastinal Organs _____	274
Posterior and Superior Mediastinum _____	281
Mediastinal Organs _____	281
Diaphragm _____	282
Coronal Sections through the Thorax _____	284
Horizontal Sections through the Thorax _____	286
Fetal Circulatory System _____	288
Mammary Gland _____	290



5 Abdominal Organs 291

Position of the Abdominal Organs _____	291
Anterior Abdominal Wall _____	293
Stomach _____	294
Pancreas and Bile Ducts _____	296
Liver _____	298
Spleen _____	300
Upper Abdominal Organs _____	301
Vessels of the Abdominal Organs _____	302
Superior Mesenteric Vessels _____	302
Portal Circulation _____	303
Superior Mesenteric Artery _____	304
Inferior Mesenteric Artery _____	305
Dissection of the Abdominal Organs _____	306
Mesenteric Arteries _____	308
Mesentery _____	310
Upper Abdominal Organs _____	311
Posterior Abdominal Wall _____	316
Pancreas and Bile Ducts _____	316
Duodenum, Pancreas, and Spleen _____	317
Root of the Mesentery and Peritoneal Recesses _____	318
Horizontal Sections through the Abdominal Cavity _____	320
Midsagittal Sections through the Abdominal Cavity _____	322



6 Retroperitoneal Organs 323

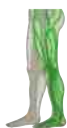Position of the Urinary Organs _____	323
Sections through the Retroperitoneal Region _____	325
Kidney _____	326
Arteries _____	328
Arteries and Veins _____	329
Retroperitoneal Region _____	330
Urinary System _____	330
Lymph Vessels and Nodes _____	332
Vessels and Nerves _____	333
Autonomic Nervous System _____	334
Male Urogenital System _____	336
Male Genital Organs (isolated) _____	337
Male External Genital Organs _____	340
Penis _____	342
Male Internal Genital Organs _____	343
Testis and Epididymis _____	343
Accessory Glands _____	344
Pelvic Cavity in the Male _____	345
Coronal Sections _____	345
Vessels of the Pelvic Organs _____	346
Abdominal Aorta _____	348
Vessels and Nerves of the Pelvic Organs _____	349
Urogenital and Pelvic Diaphragms in the Male _____	350
Female Urogenital System _____	354
Female Genital Organs (isolated) _____	356
Female Internal Genital Organs _____	358
Uterus and Related Organs _____	359
Arteries and Lymph Vessels _____	360
Female External Genital Organs _____	361
Urogenital Diaphragm and External Genital Organs in the Female _____	363
Pelvic Cavity in the Female _____	366
Coronal and Horizontal Sections _____	367



7 Upper Limb

368

Skeleton of the Shoulder Girdle and Thorax _____	368
Scapula _____	371
Skeleton of the Shoulder Girdle and Humerus _____	372
Humerus _____	373
Skeleton of the Forearm _____	374
Skeleton of the Forearm and Hand _____	375
Skeleton of the Hand _____	376
Joints and Ligaments of the Shoulder _____	378
Ligaments of the Elbow Joint _____	379
Ligaments of the Hand and Wrist _____	380
Muscles of the Shoulder and Arm _____	382
Dorsal Muscles _____	382
Pectoral Muscles _____	384
Muscles of the Arm _____	386
Muscles of the Forearm and Hand _____	388
Flexor Muscles _____	388
Extensor Muscles _____	392
Muscles of the Hand _____	394
Arteries _____	396
Veins _____	398
Nerves _____	399
Surface Anatomy of the Upper Limb _____	401
Posterior and Lateral Aspects _____	401
Anterior Aspect _____	402
Neck and Shoulder _____	403
Shoulder _____	404
Posterior Region _____	404
Anterior Region _____	406
Shoulder and Arm _____	408
Axillary Region _____	410
Brachial Plexus _____	413
Arm _____	414
Cubital Region _____	416
Forearm and Hand _____	420
Posterior Region _____	420
Anterior Region _____	422
Hand _____	424
Posterior Region _____	424
Anterior Region _____	426
Sections through the Upper Limb _____	430



8 Lower Limb

432

Skeleton of the Pelvic Girdle and Lower Limb _____	432
Bones of the Pelvis _____	433
Skeleton of the Pelvis _____	435
Bones of the Hip Joint _____	438
Femur _____	439
Skeleton of the Leg _____	440
Bones of the Knee Joint _____	441
Skeleton of the Foot _____	442
Ligaments of the Pelvis and Hip Joint _____	444
Knee Joint _____	446
Ligaments of the Knee Joint _____	447
Joints of the Ankle _____	449
Ligaments of the Foot _____	450
Muscles of the Thigh _____	452
Adductor Muscles _____	452
Gluteal Muscles _____	454
Flexor Muscles _____	455
Muscles of the Leg _____	457
Flexor Muscles _____	457
Muscles of the Leg and Foot _____	458
Deep Flexor Muscles _____	460
Extensor Muscles _____	462
Muscles of the Foot _____	463
Arteries _____	466
Veins _____	468
Nerves _____	470
Lumbosacral Plexus _____	471
Lumbar Part of the Vertebral Canal and Spinal Cord _____	472
Spinal Cord with Intercostal Nerves _____	474
Spinal Cord and Lumbar Plexus _____	475
Surface Anatomy of the Lower Limb _____	476
Posterior Aspect _____	476
Anterior Aspect _____	477
Thigh _____	478
Anterior Region _____	478
Gluteal Region _____	482
Thigh _____	484
Posterior Region _____	484
Knee and Popliteal Fossa _____	486
Crural Region _____	489
Crural Region and Foot _____	492
Coronal Sections through the Foot _____	495
Sections through the Lower Limb _____	496
Foot _____	498
Posterior Region _____	498
Anterior Region _____	500

This Color Atlas of Anatomy features full-color photographs of actual cadaver dissections. Reference Manual on Scientific Evidence: Third Edition. 2011. 10.53 MB. 76,326 Downloads. New! Sobotta - Atlas of Human Anatomy with online access: the exam atlas for understanding, learn Systems Thinking, : Managing Chaos and Complexity: A Platform for Designing Business Architecture. 2005. 4.09 MB. 115,041 Downloads. New! The first edition of Systems Thinking was the first book to develop a working concept of systems. Animal, Vegetable, Miracle: A Year of Food Life. 383 Pages. 2010. 2.28 MB. 34,742 Downloads.

Barbara_Kingsolver,_Camille_Kingsolver,_Steven_L_(zlibraryexau2g3p_onion).pdf This colour atlas provides an introduction to how birds are constructed. It is concerned principally with the economically important species, but, where their anatomy significantly differ, the more common caged birds are dealt with. The book is planned around certain body systems including the integument and skeleton and digestive, urogenital and respiratory tracts. Lymphoid tissue, blood vessels and nerves are dealt with as they occur in association with these systems. In some instances, a straight topographical approach is taken. Most of the photographs are of fresh, unfixed material, some with PDF | On Jan 1, 2004, Marijana Lisak published Color Atlas of Human Anatomy. Volume 1: Locomotor System | Find, read and cite all the research you need on ResearchGate. The book's didactic utility. The Color Atlas of Neurology is, without doubt, an illustrative handbook and epigrammatic reference for medical students and residents, neurologists, even neurosurgeons, and primary care practitioners, who confront neurologic issues in their daily practice. This small atlas is a precious and unique visual guide to neurology's most difficult concepts, a book that should always be close at hand and be.